
hoog risico longembolieën

Hugo Touw – anesthesioloog-intensivist

ketenavond longembolie 2026

Radboudumc

Inhoud

Hoofdstukken	Specifieke aandachtspunten
Epidemiologie	Incidentie, mortaliteit hoog risico longembolieën
Klinische presentatie	Hemodynamiek
Behandeling	1) Trombolyse 2) Endovasculaire behandeling 3) Chirurgie 4) ECMO
	<i>Pulmonary Embolism Rescue Team (PERT)</i> Acute Long Embolie Response Team (ALERT)
Follow-up	Monitoring, IC behandeling.

Mevrouw Blauw

60jr

VG-

Vitals:

bloeddruk:

95/55 mmHg

hartslag:

110 p/m

ademhalingsfrequentie:

22 p/m

SpO₂

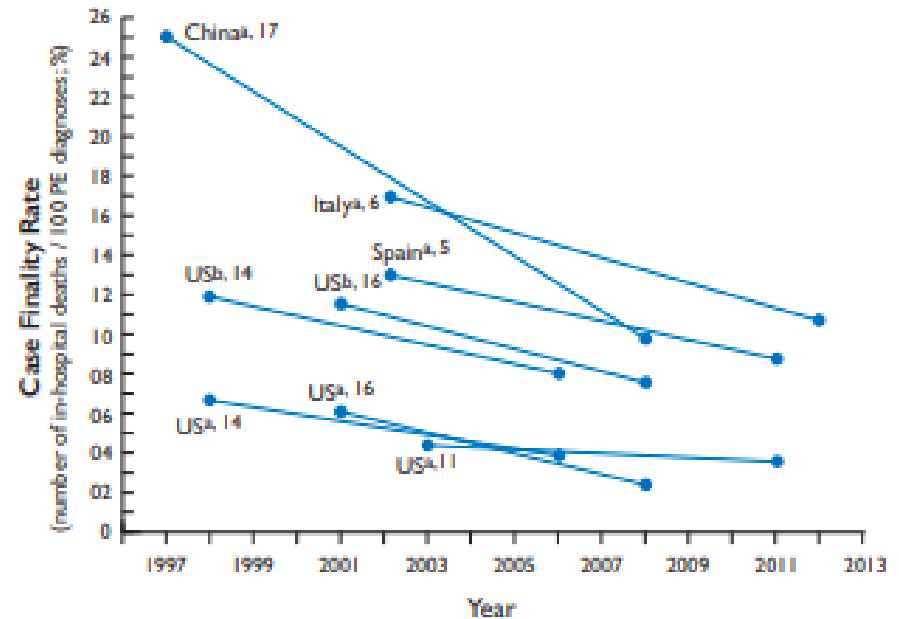
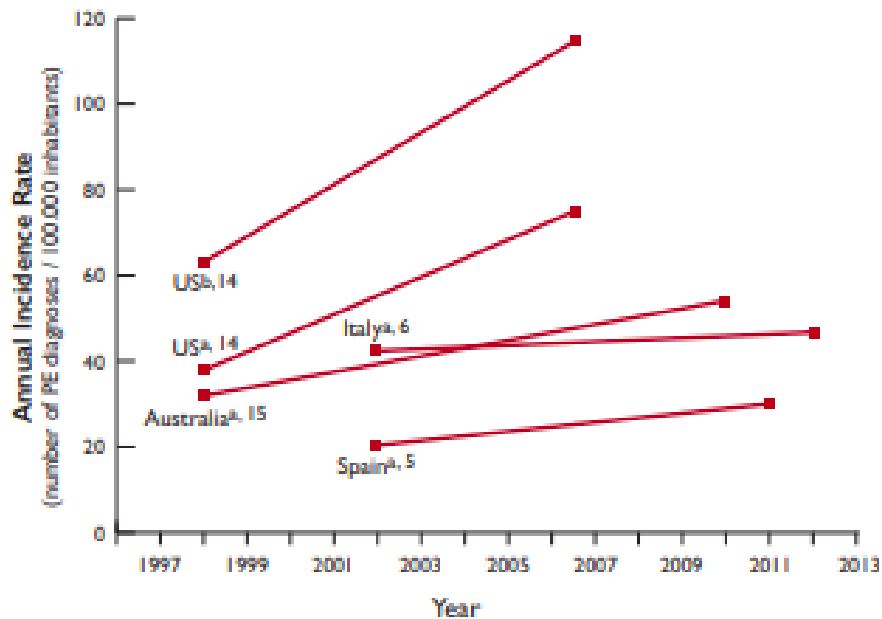
92%



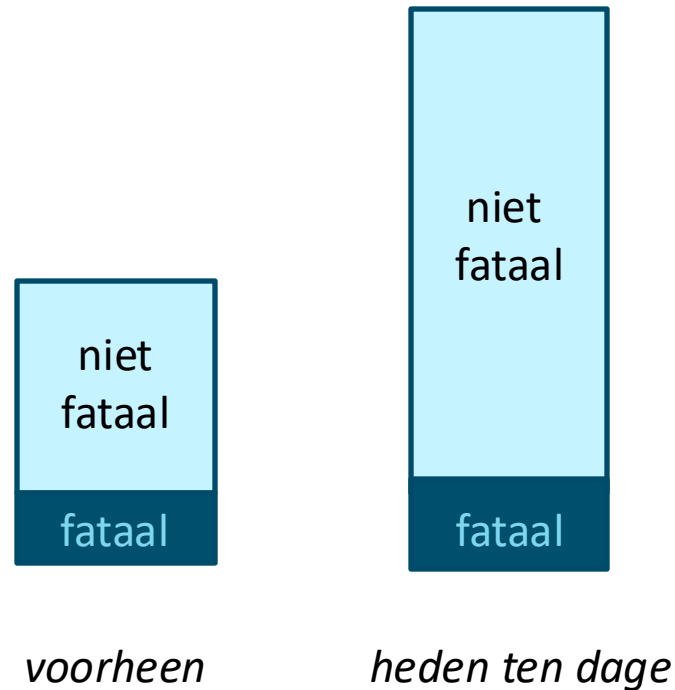
Hoog risico = haemodynamische instabiliteit

Systolische bloeddruk <90 mm Hg

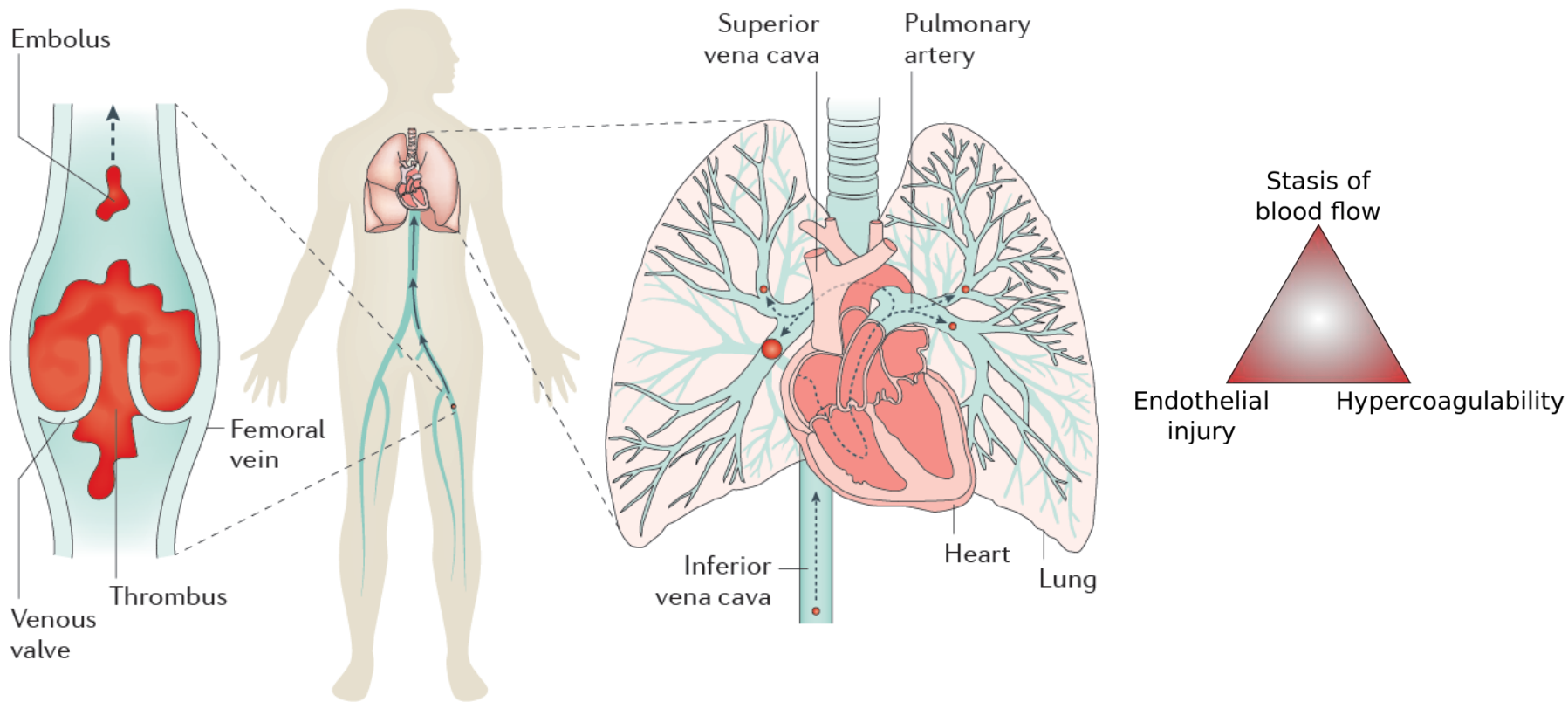
Incidentie / Mortaliteit



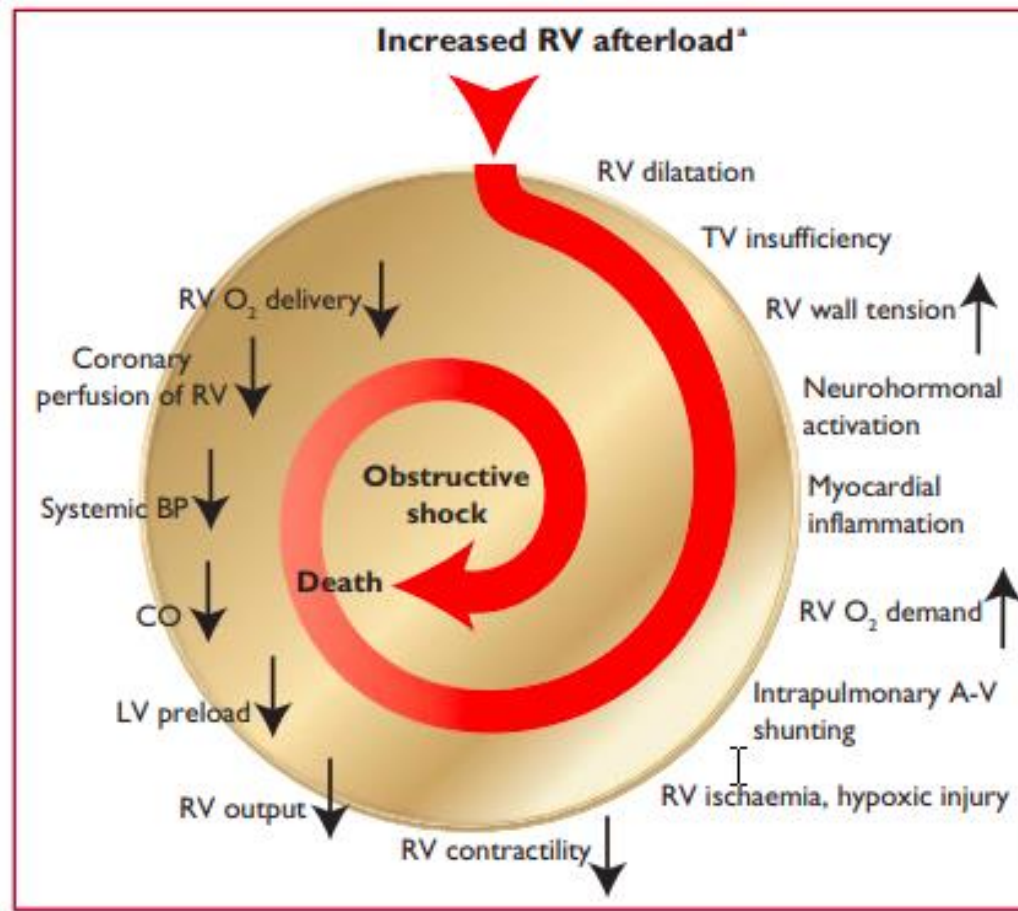
Ontwikkeling incidentie van PE



Klinische presentatie



Haemodynamische instabiliteit



Hoog Risico

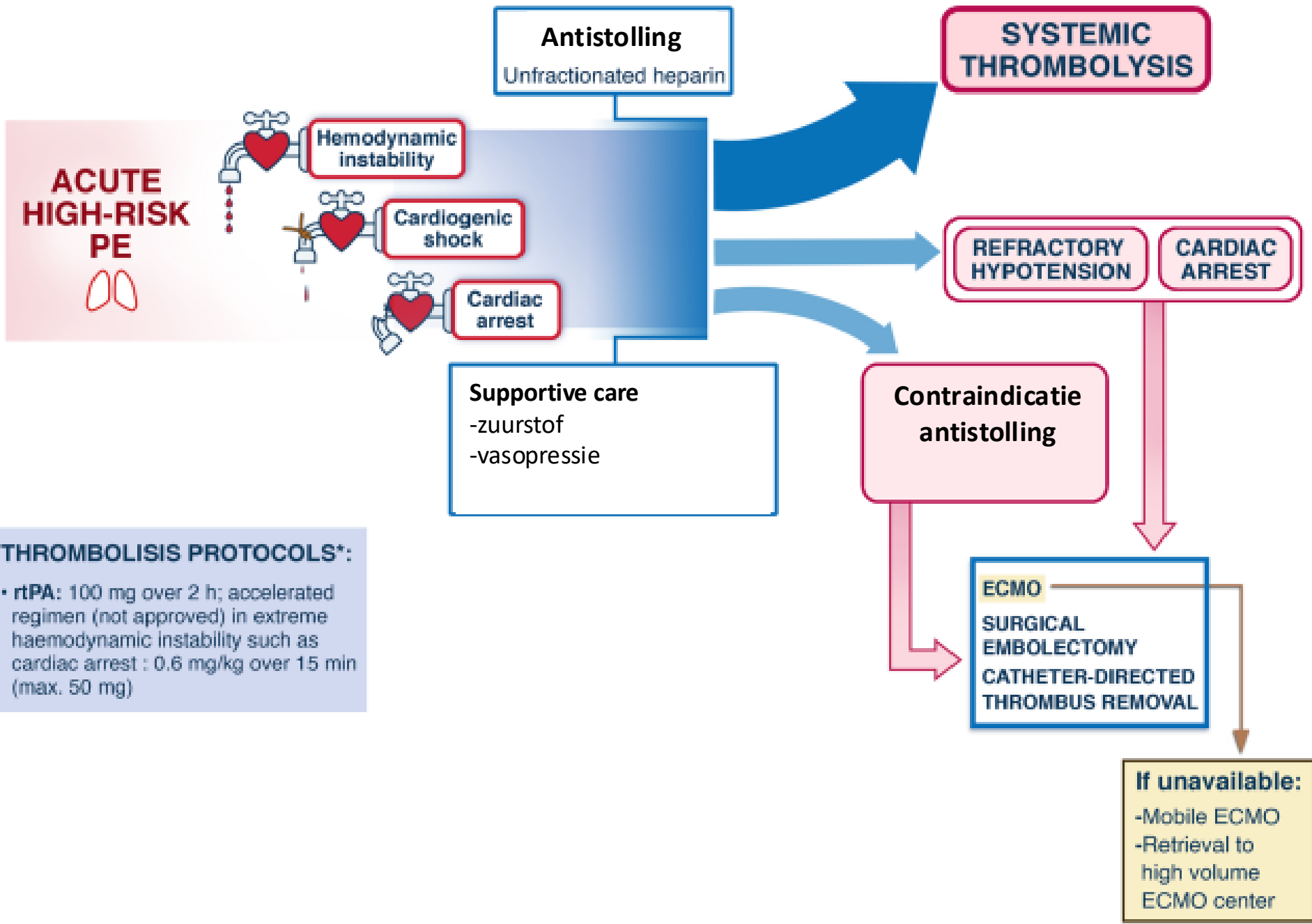


Fig. 1 Management of high-risk pulmonary embolism in the intensive care unit. Thrombolysis protocols and absolute contraindications to thrombolysis are based on the ESC/ERS guidelines [1]. CNS central nervous system
Helms, Carries and Klok ICM 2023

Contraindicaties trombolyse

Absolute contraindicaties:

- Hemorragische beroerte of beroerte van onbekende oorsprong op enig moment
- Ischemische beroerte in de voorafgaande 6 maanden
- Beschadiging van het centrale zenuwstelsel of CZS-tumoren
- Recent groot trauma / operatie / hoofdletsel in de afgelopen 3 weken
- Gastro-intestinale bloeding in de afgelopen maand
- Bekend verhoogd bloedingsrisico

Relatieve contraindicaties:

- TIA (*transient ischemic attack*) in de voorafgaande 6 maanden
- Gebruik van orale anticoagulantia
- Zwangerschap of binnen één week postpartum
- Niet-comprimeerbare punctieplaats
- Traumatische reanimatie
- Refractaire hypertensie (systolische bloeddruk >180 mm Hg)
- Gevorderde leverziekte
- Infectieuze endocarditis
- Actieve maagzweer (peptisch ulcus)

ESC 2019

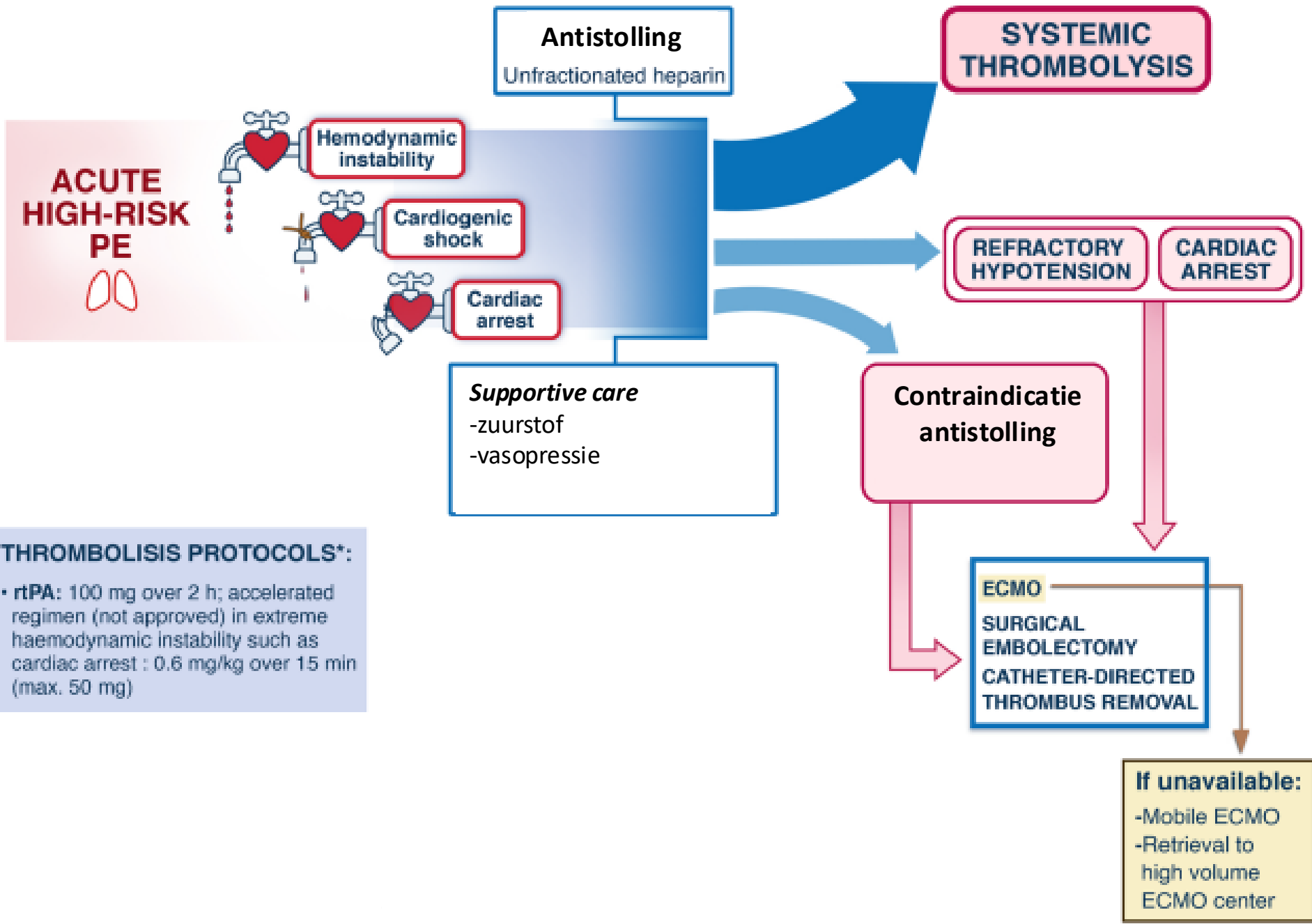
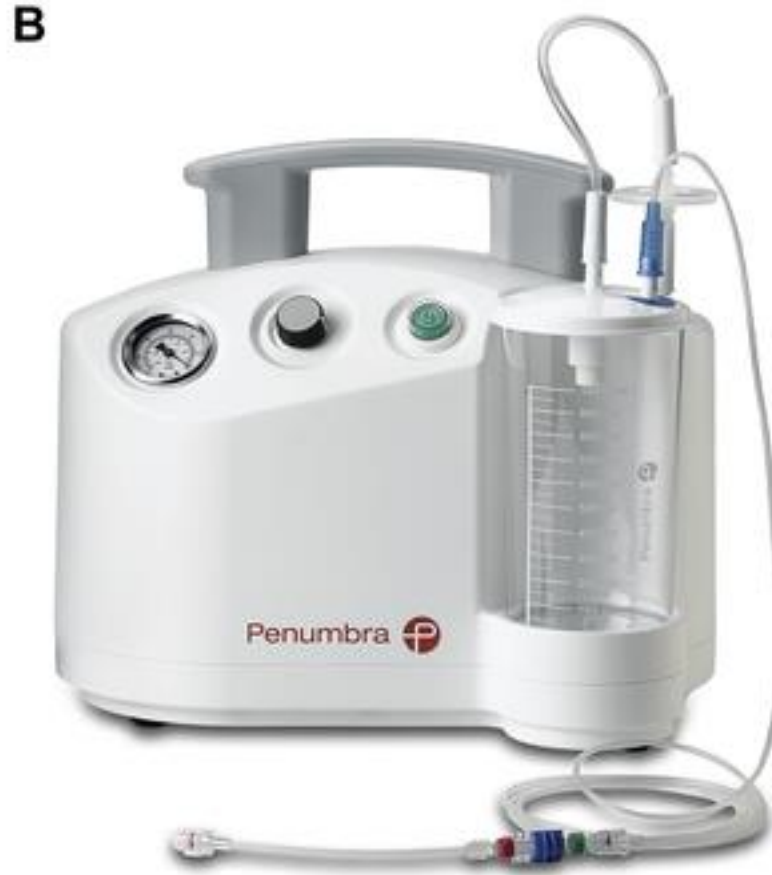

Fig. 1 Management of high-risk pulmonary embolism in the intensive care unit. Thrombolysis protocols and absolute contraindications to thrombolysis are based on the ESC/ERS guidelines [1]. CNS central nervous system
Helms, Carries and Klok ICM 2023

Catheter directed therapy



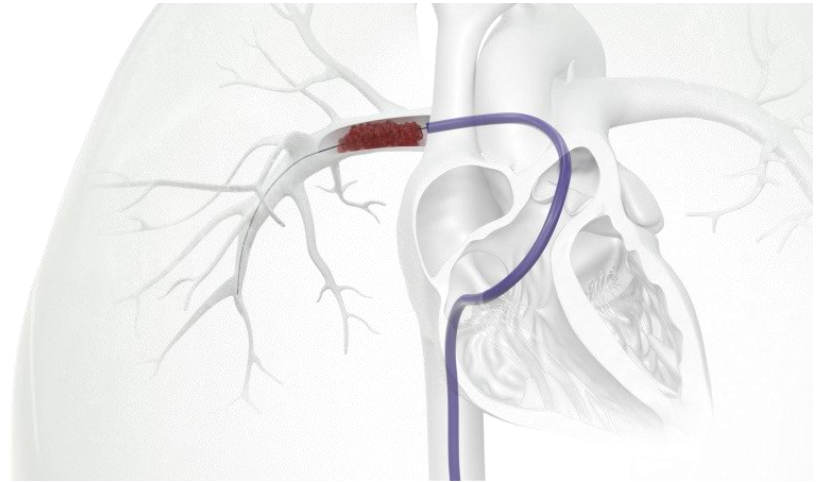
FlowTrievers[®] INARI medical



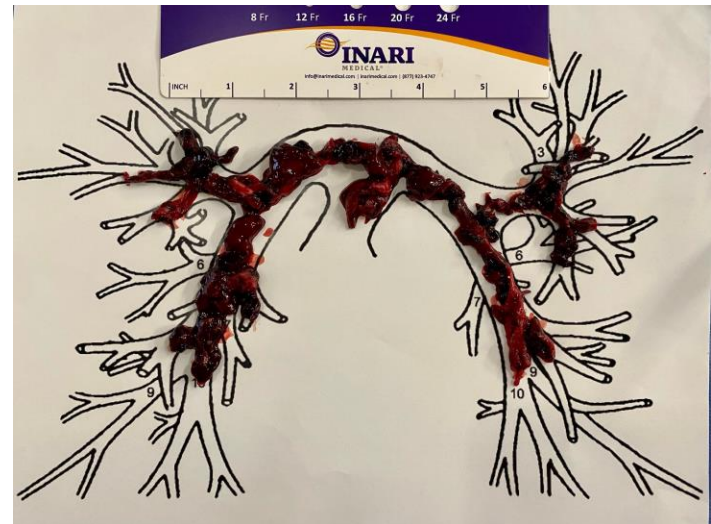
Indigo[™] System Penumbra

Inari FlowTrievers

6. Inbrengen Trievers24 over stijve draad



Inari FlowTrievers



TORPEO-NL

LU
MC Leids Universitair
Medisch Centrum



**MAASSTAD
ZIEKENHUIS**
een santeon ziekenhuis



dr. Corstiaan den Uijl
Cardioloog-Intensivist
Maastricht Ziekenhuis
Principal investigator TORPEO-NL

U UMC Utrecht

Amsterdam UMC
Universitair Medische Centra

W Noordwest
Ziekenhuisgroep

Amphia



Rijnstate

Isala

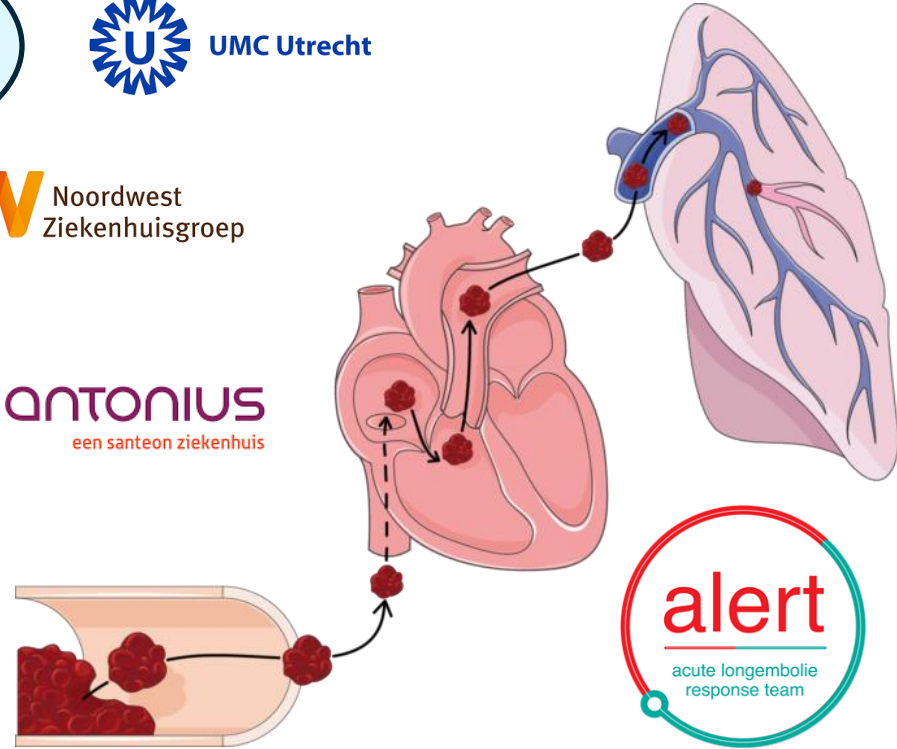
ST ANTONIUS
een santeon ziekenhuis

catharina
een santeon ziekenhuis

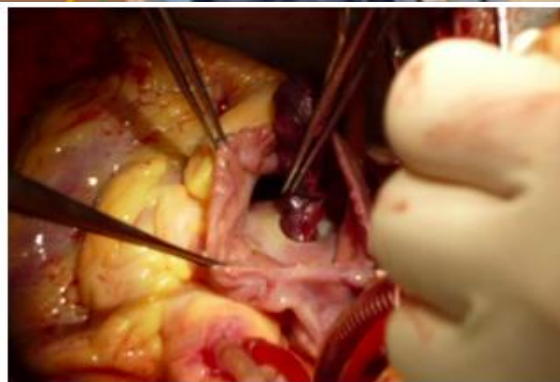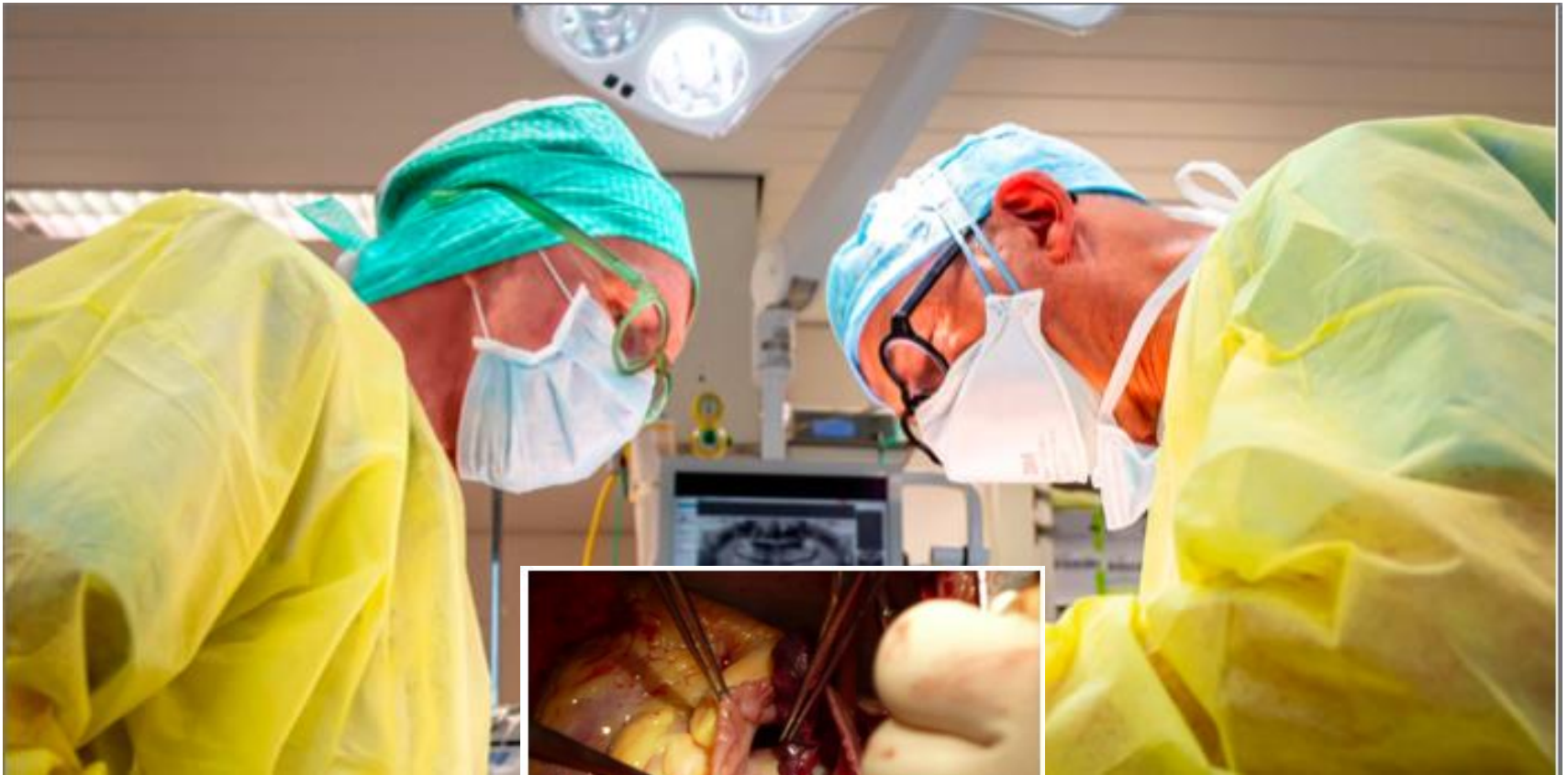H+
MC Radboudumc

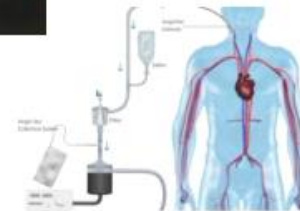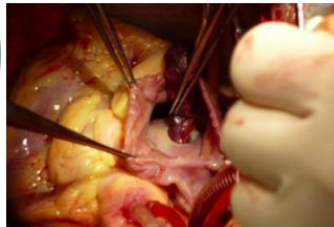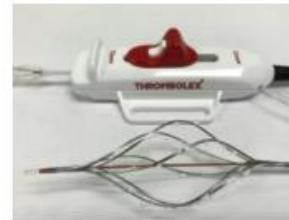Erasmus MC
Universitair Medisch Centrum Rotterdam

Maastricht UMC+






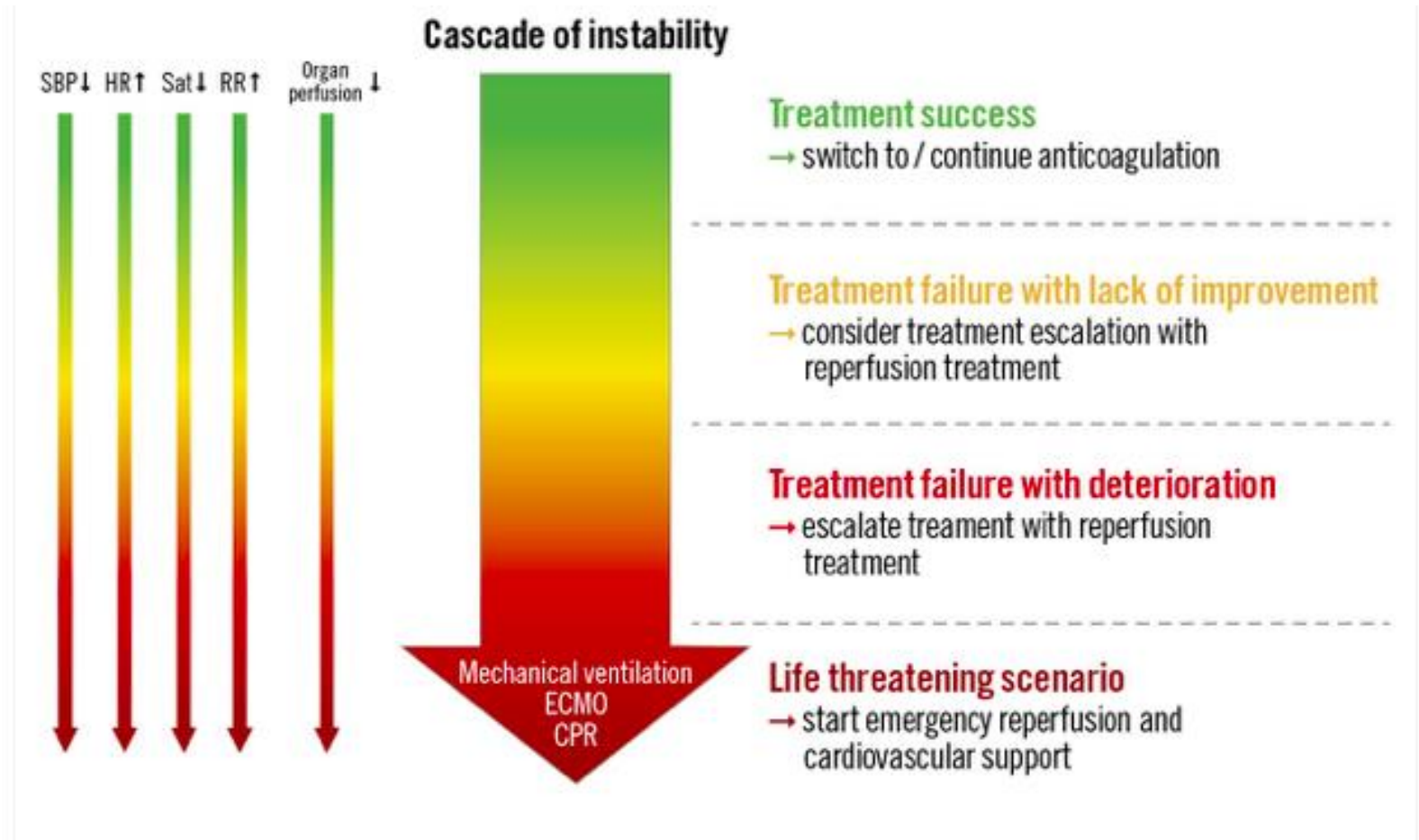
Cardio-Thoracale Chirurgie



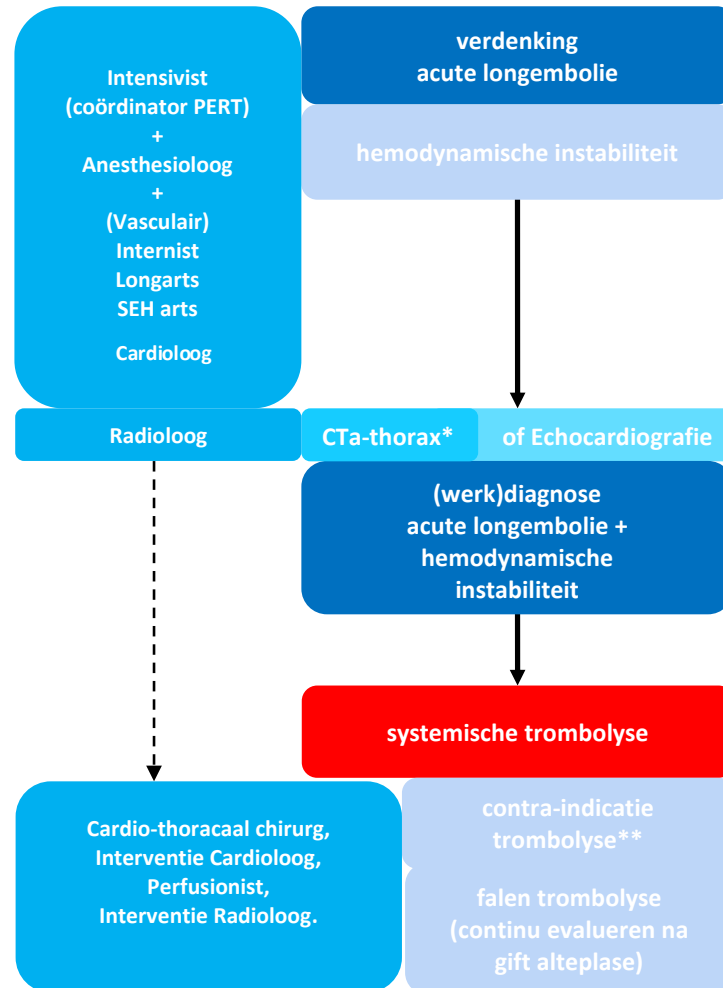


PERT / ALERT

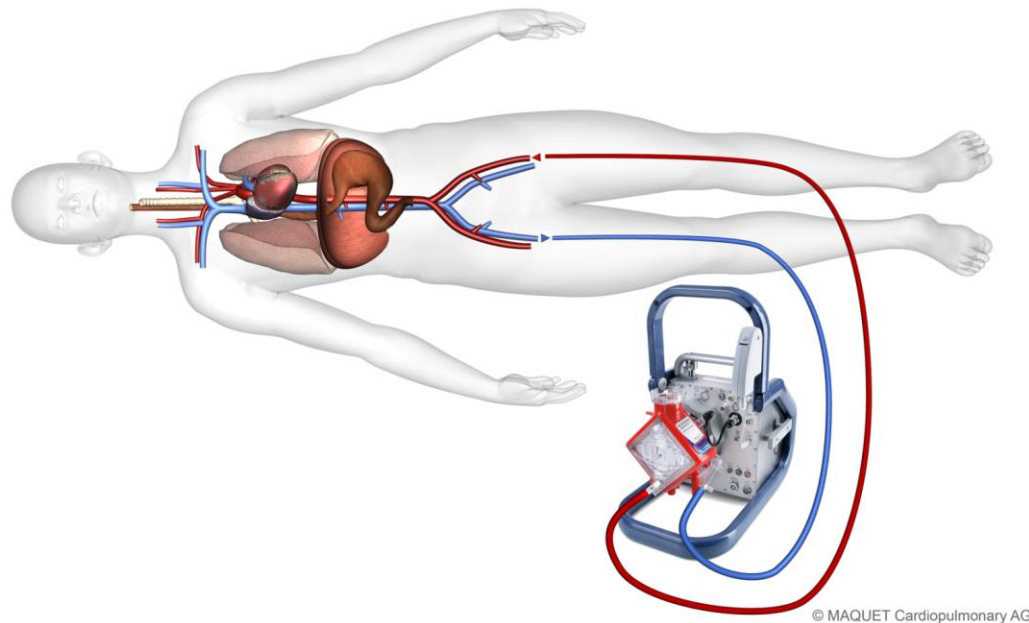




protocol Radboudumc



VA-ECMO



ECMO op de heli – *OnScene trial*

- geschatte leeftijd tussen 18 en 50 jaar
- een initieel schokbaar ritme
 - óf pulseless electrical activity (PEA) bij een vermoeden op longembolie.
- *Witnessed arrest* of tekenen van leven
- Refractaire hartstilstand

Trombolysse faalt (of gecontraïndiceerd) wat dan?

1) Pulmonary Embolism Rescue Team (PERT)

2) Behandeltechnieken


Endovasculaire behandeltechnieken

Chirurgie

ECMO

Intensive Care behandelings

we should



RV



Afsluitende Casus – deel 1

- Man van 67 jaar.
- SEH. Kortademig, geen pijn op de borst.
 - Witnessed arrest op SEH
 - 14 blokken reanimatie o.b.v. PEA
 - 06:50 start Alteplase
 - 07:20 ROSC

Afsluitende casus – deel 2

- ABG na ROSC:
 - pH 6,80/pCO₂ 10,0/pO₂ 10,4/HCO₃ 11,5/BE -23,0/lactaat 13,8
- Start Nor

- Persisterende shock:
 - Start ECMO 9:00

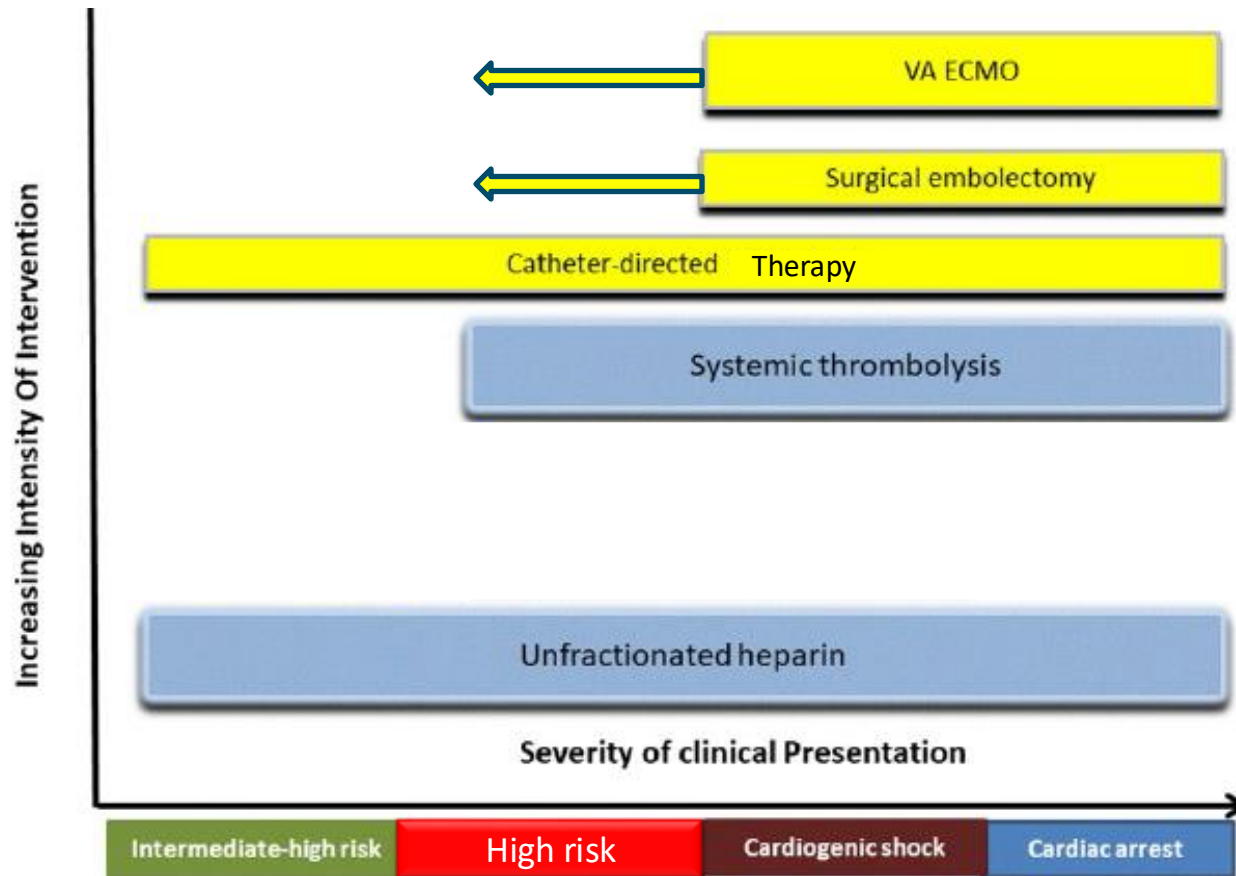
- Decanulatie
- Detubatie
- Ontslag
- Herstel

Conclusie

**Multidisciplinair
Multimogelijkheden**

#Maatwerk

Conclusie

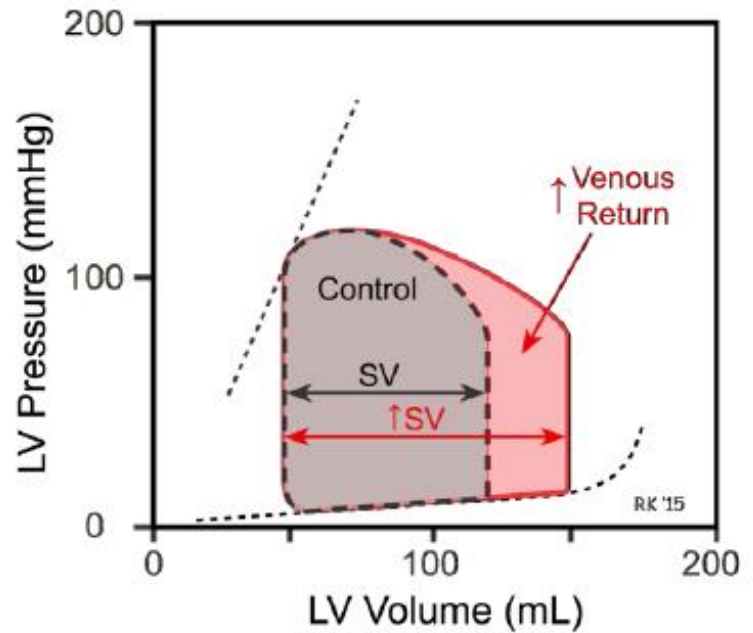
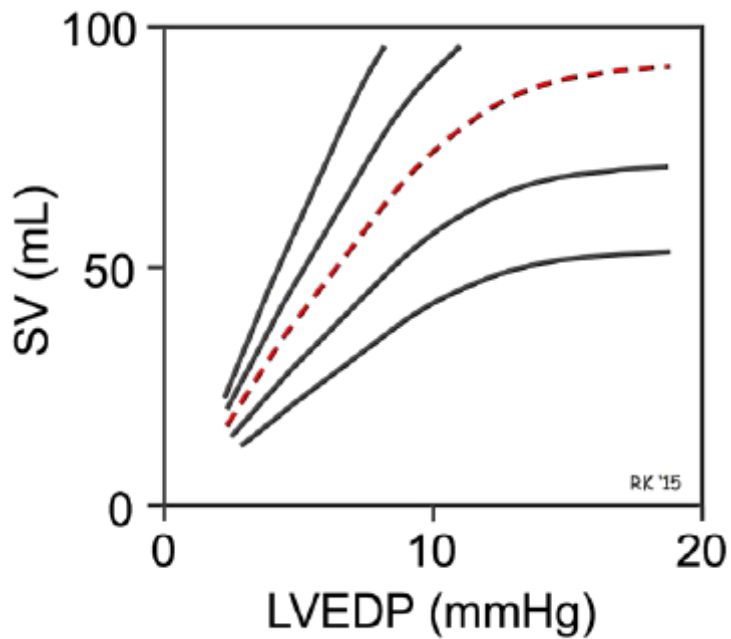
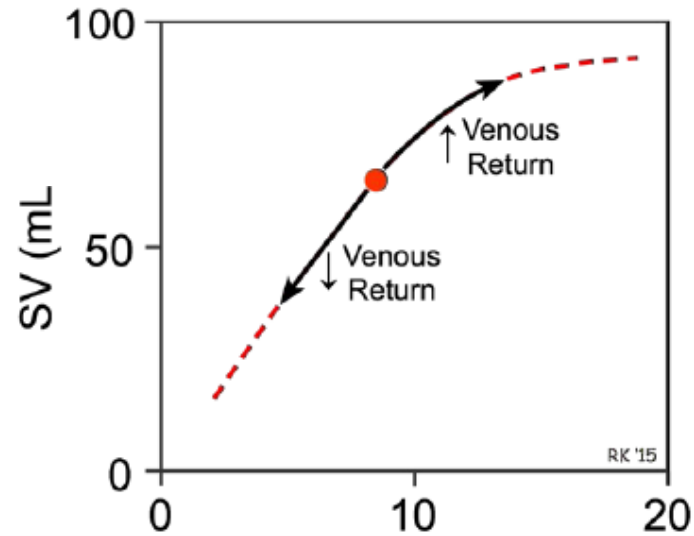


(adjusted from) Aissaoui ICM 2018


we all



LV



we should all



RV



Right ventricular failure

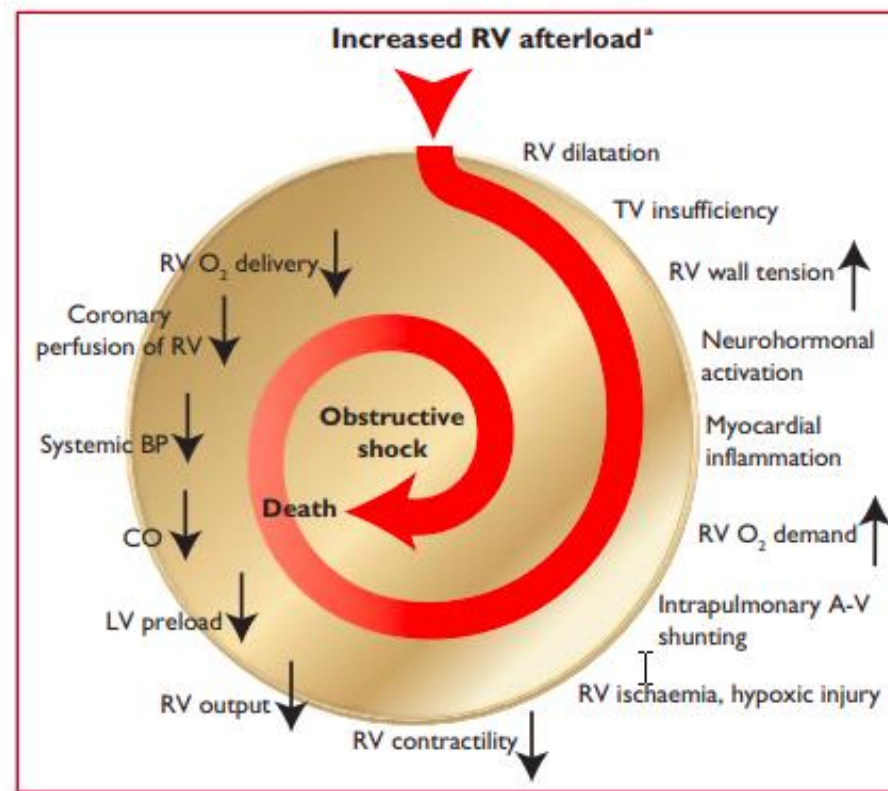
De kapstok

Early mortality risk		Indicators of risk			
		Haemodynamic instability ^a	Clinical parameters of PE severity and/or comorbidity: PESI class III–V or sPESI \geq 1	RV dysfunction on TTE or CTPA ^b	Elevated cardiac troponin levels ^c
High		+	(+) ^d	+	(+)
Intermediate	Intermediate–high	-	+ ^e	+	+
	Intermediate–low	-	+ ^e	One (or none) positive	
Low		-	-	-	Assesment optional; if assessed, negative

©ESC 2019

Haemodynamic collapse

Acute pulmonary embolism



ECS 2019

IC treatment -> Judith van den Brule

Verlagen pulmonale vaatweerstand

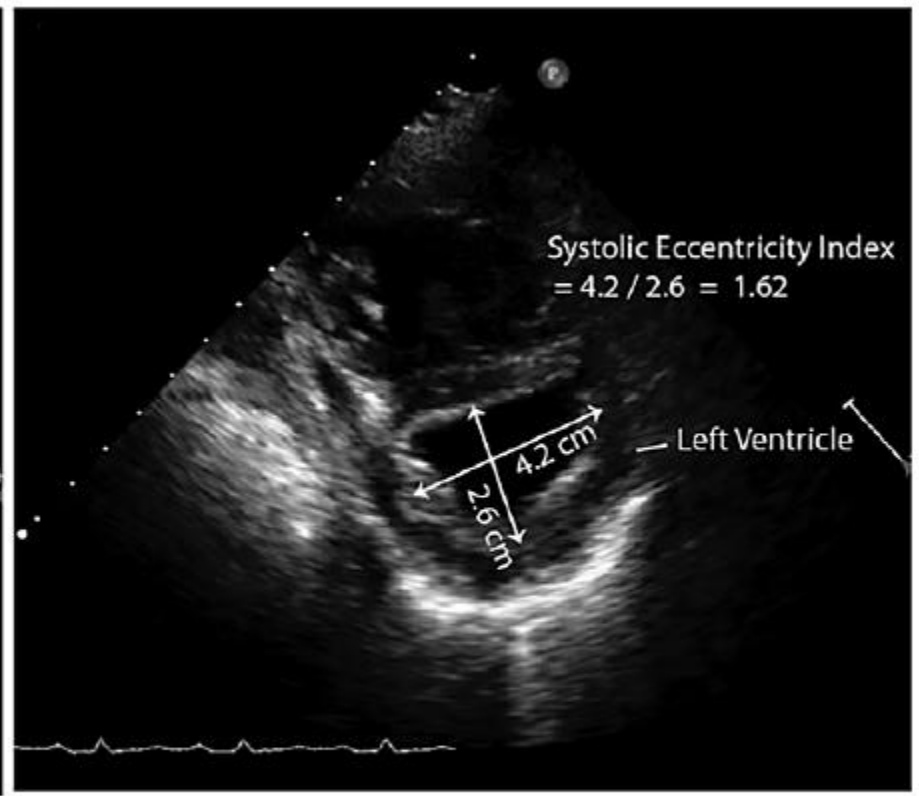
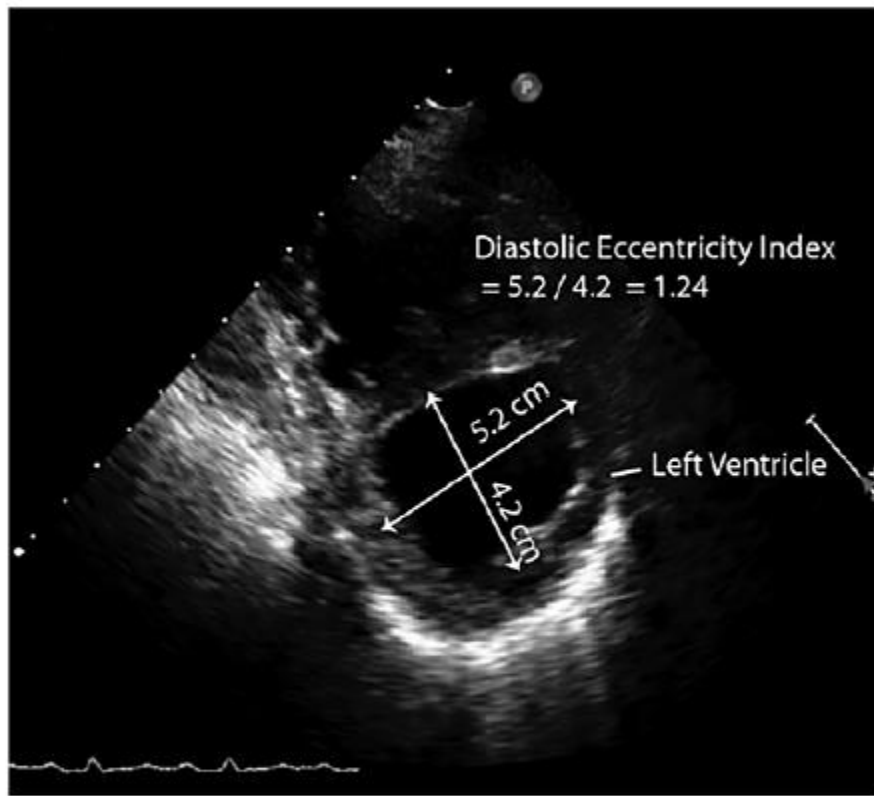
- Flolan (epoprostenol) vernevelingen
=NO beademing
 - Maar goedkoper
- Rescue
 - Milrinone / Enoximone vernevelingen

Beademing

- PEEP

Vasopressor keuze

Echo

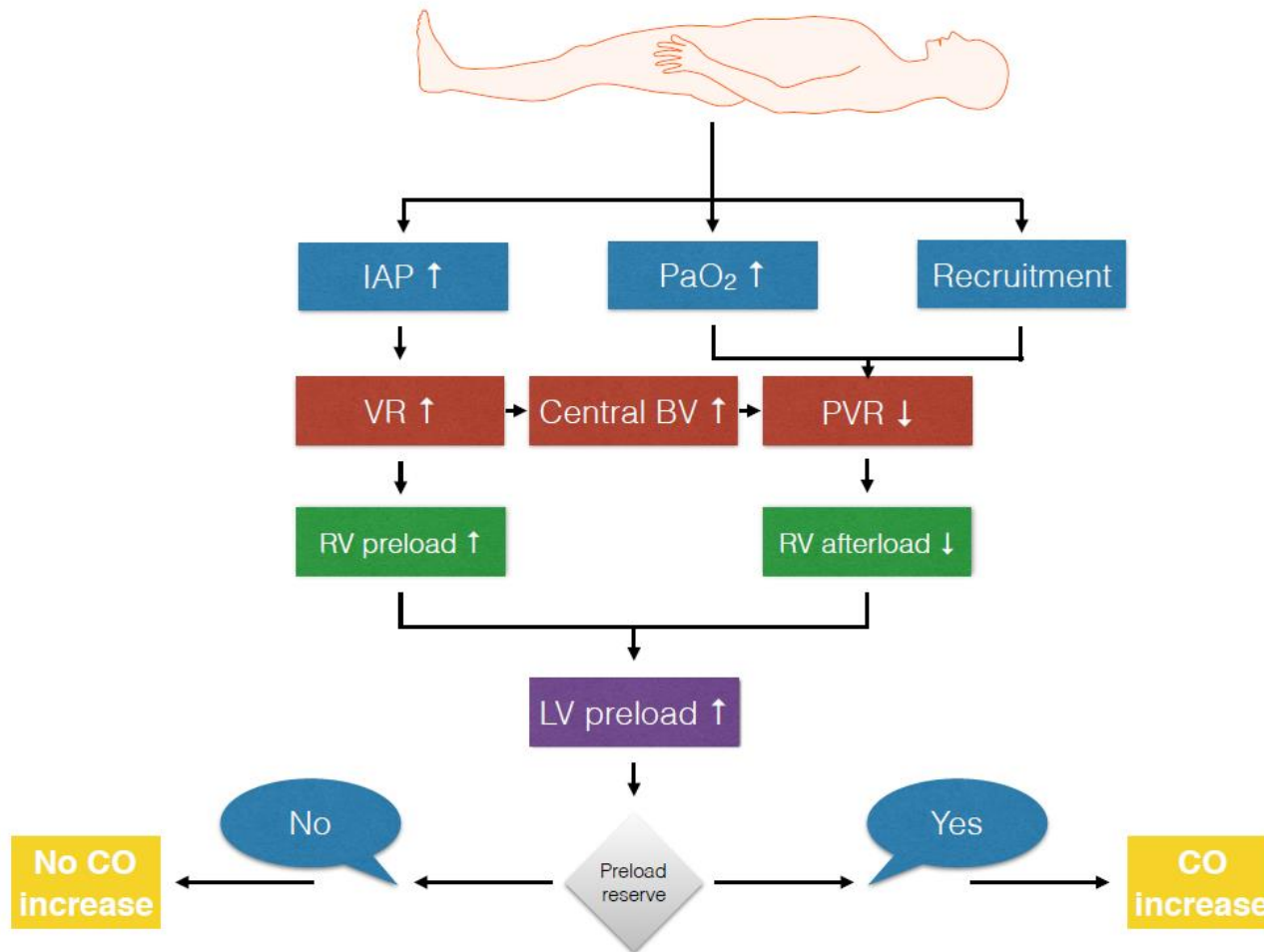


Vasopressors

Norepinephrine in case of severe systemic hypotension to improve RCA perfusion.

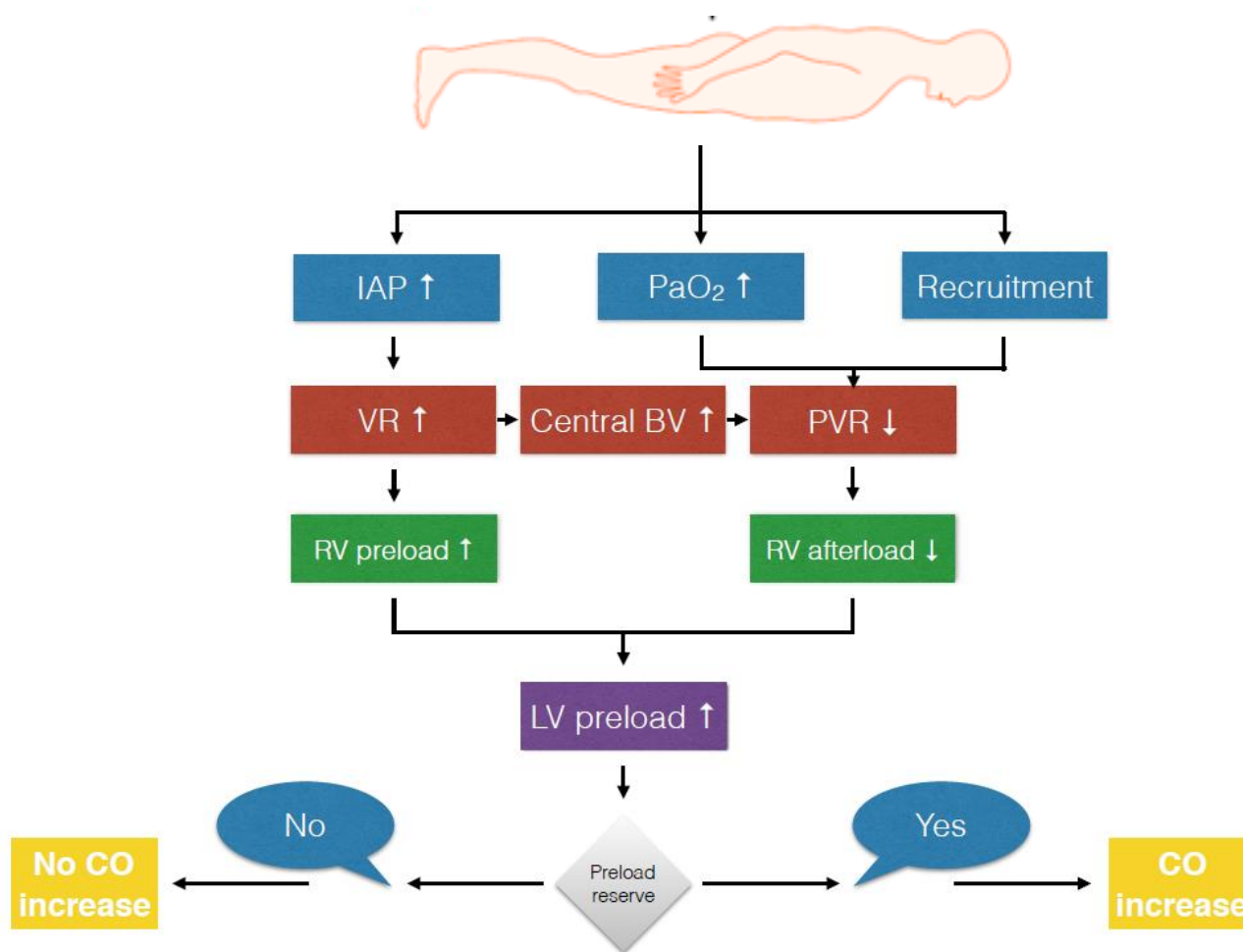
Vasopressine 

Could prone positioning be useful in RV failure?




Jozwiak et al. 2013 Am J Respir Crit Care Med

Could prone positioning be useful in RV failure?



Jozwiak et al. 2013 Am J Respir Crit Care Med

we should



RV

